

## Giant Hepatic Haemangioma: A Case Report

Imam H,<sup>1\*</sup> Rahman MA,<sup>2</sup> Rahim MA,<sup>3</sup> Ahmed QM,<sup>4</sup> Hasan MN,<sup>5</sup> Islam MS,<sup>6</sup> Rahman MR<sup>7</sup>

### Abstract

Hepatic haemangioma is a benign tumour of liver. Larger hepatic haemangioma is labeled as giant hepatic haemangioma. Most cases remain asymptomatic. It can cause diagnostic dilemma which leads to uncertain management options. We present a case of 28 – year – old woman who presented with abdominal discomfort for one year. Ultrasonogram of abdomen showed multiple space occupying lesions in the liver. It is difficult to differentiate hepatic haemangioma from other space occupying lesions of liver. MRI of liver showed characteristic features of hepatic haemangioma. Patient was diagnosed as giant hepatic haemangioma. She was discharged with the advice for follow up.

[Shaheed Syed Nazrul Islam Med Col J 2019, Jan; 4 (1):166-169]

**Key Words:** Liver, Asymptomatic, Giant haemangioma.

### Introduction

Haemangioma is the commonest benign tumour of the liver.<sup>1</sup> Women are affected more with a F:M of up to 5:1.<sup>2</sup> Most cases of haemangioma remain asymptomatic and often detected incidentally by non-invasive imaging giving rise to the problem of diagnostic dilemma and uncertain management options. Giant haemangioma is defined as tumour sized 4cm

and above.<sup>3</sup> It is seen as big as 27cm. It can cause significant pressure effects and complicate with intra-lesional haemorrhage, infection. Needle aspiration for diagnostic purpose may complicate with profuse haemorrhage. Surgical treatment option is best reserved for haemangioma causing pressure effect or haemorrhage.

1. Dr. Hasan Imam, Assistant Professor, Department of Internal Medicine, Bangabandhu Sheikh Mujib Medical University, Shahbag, Dhaka
2. \*Dr. Md. Atikur Rahman, Resident, Department of Internal Medicine, Bangabandhu Sheikh Mujib Medical University, Shahbag, Dhaka. medicmmc@gmail.com , dr.atik24@gmail.com
3. Professor Dr. Md. Abdur Rahim, Department of Internal Medicine, Bangabandhu Sheikh Mujib Medical University, Shahbag, Dhaka
4. Dr. Quazi Mamtaz Uddin Ahmed, Associate professor, Department of Internal Medicine, Bangabandhu Sheikh Mujib Medical University, Shahbag, Dhaka
5. Dr. Md. Nazmul Hasan, Assistant professor, Department of Internal Medicine, Bangabandhu Sheikh Mujib Medical University, Shahbag, Dhaka
6. Dr. Mohammad Syedul Islam, Research assistant, Department of Internal Medicine, Bangabandhu Sheikh Mujib Medical University, Shahbag, Dhaka
7. Dr. Md. Rajibur Rahman, Resident , Department of Internal Medicine, Bangabandhu Sheikh Mujib Medical University, Shahbag, Dhaka

\* For correspondence

### Case Report

A 28-years-old woman was admitted to the department of Internal Medicine in BSMMU with abdominal discomfort for one year. Before admission she consulted a physician where she underwent ultrasonogram of abdomen that revealed hepatic multiple space occupying lesions. She had no fever, bleeding manifestation, abdominal pain, alteration of bowel habit. There was no weight loss, her appetite was good. She did not take OCP. Physical examination revealed mild anaemia, no lymphadenopathy or organomegaly.

Laboratory investigations revealed Haemoglobin 10.1gm/dl, ESR 24 mm in 1<sup>st</sup> hour and WBC TC-  $7 \times 10^9$ /L. Liver function test revealed ALT 18 U/L, ALP-87 U/L. USG of abdomen showed mild hepatomegaly having

multiple (at least four) solid echogenic masses in both lobes of liver, largest one measured 8×8 cm in right lobe of liver, parenchyma is homogeneous, no ascites or lymphadenopathy, Chest X-ray found normal, HBsAg and Anti HCV were negative. Alphafetoprotein – 2.21 ng/ml, CA 19.9 was 4.4 U/ml, CA 125 was 9.01 U/ml, CEA was 0.97 ng/ml. MRI of Liver with contrast revealed hepatomegaly (16 cm liver), hyperintense well-circumscribed lobulated lesion (11.5×9×8.7cm) at segment VII & VIII at right lobe of liver which after contrast shows peripheral nodular enhancement (Fig: 1A, 1B, 2). Multiple similar lesions of variable sizes were seen on rest of the liver. Patient was diagnosed as a case of giant hepatic haemangioma and was discharged with advice for follow up in the department of hepatobiliary surgery.

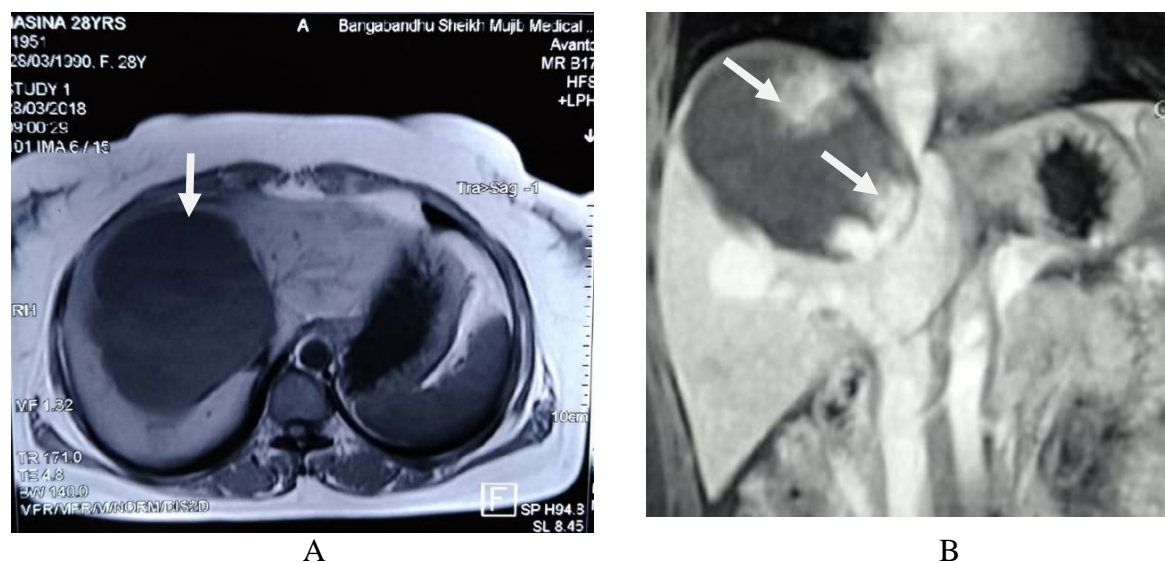


Fig 1. (A) MRI T1 noncontrast image showing hypointense lesion on liver (B). MRI contrast image showing peripheral nodular discontinuous enhancing lesion on liver



## References

1. Caseiro AF, Brito J, Araujo AE, Belo SP, Rodrigues H, et al. Liver haemangioma: common and uncommon findings and how to improve the differential diagnosis. *Eur Radio* 2007; 17(6): 1544-1554.
2. Weerakkody Y. Hepatic haemangioma Radiology Reference Article Radiopaedia.org [Internet]. Radiopaedia.org. 2018 [cited 17 August 2018]. Available from: <https://radiopaedia.org/articles/hepatic-haemangioma-3>
3. Hao F, Yang X, Tian Y, Wang W, Ge M. Spontaneous internal hemorrhage of giant hepatic hemangioma. *Medicine*. 2017;96(47):e8702
4. Choi BY, Nguyen MH. The diagnosis and management of benign hepatic tumors. *J Clin Gastroenterol* 2005; 39(5): 401-412.
5. Gupta S, Agarwal V, Acharya AN. Spontaneous rupture of a giant hepatic hemangioma - report of a case. *Indian J Surg* 2012;74:434-6.
6. Nichols FCIII, van Heerden JA, Weiland LH. Benign liver tumors. *SurgClin North Am* 1989;69:297-314.
7. Nelson RC, Chezmar JL. Diagnostic approach to hepatic hemangiomas. *Radiology* 1990;176:11-3.
8. Malagari K, Alexopoulou E, Dourakis S, Kelekis A, Hatzimichail K, et al. Transarterial embolization of giant liver hemangiomas associated with Kasabach-Merrit syndrome; a case report. *Acta Radiol* 2007; 48(6): 608-612.
9. Kievit CM, Nuis RJ, Dees A. Management of Giant Hepatic Hemangiomas: A Case Report. *MOJ Clin Med Case Rep* 2015;2(4): 00030. DOI: 10.15406/mojcr.2015.02.00030.
10. Toro A, Mahfouz AE, Ardiri A, et al. What is changing in indications and treatment of hepatic hemangiomas: a review. *Ann Hepatol* 2014;13: 327-39.